COMPARISON OF THE EFFICACY OF HYDROGEL BIOMATERIAL PREPARATION FROM SILK WASTE PROTEINS AND COMMERCIAL PRODUCT FOR DEEP WOUND HEALING IN GUINEA PIGS

Phulsuksombati P[1], Pongpat S[2], Suwannasing S[3], Pilakasiri K[3], and Sangjun N[1]

1 Armed Forces Research Institute of Medical Sciences, Bangkok, Thailand, 2 Office of Atoms for Peace, Ministry of Science and Technology, Bangkok, Thailand, 3 Faculty of Medicine, Siriraj Hospital, Mahidol University, Bangkok, Thailand

บทคัดย่อ

การศึกษาประสิทธิภาพของวัสดุปิดแผลที่เตรียมจากโปรตีนไหมในรูปของไฮโดรเจลเทียบกับวัสดุปิดแผลคิวติโนวา ไฮโดร ต่อการหายของแผลลึก ศึกษาจากหนูตะเภาเพศเมียจำนวน 12 ตัว โดยแบ่งหนูตะเภาออกเป็น 6 กลุ่ม กลุ่มละ 2 ตัว ซึ่งแบ่งตามวันที่ทำการเก็บชิ้นเนื้อ โดยแต่ละกลุ่มห่างกัน 3 วัน เริ่มจากวันที่ 3 ถึงวันที่ 18 หลังจากวันที่ทำการสร้างแผล นำหนูตะเภาทั้งหมดมาทำการสร้างแผลลึก 2 แผล ที่ด้านซ้ายและ ด้านขวาบริเวณผิวหนังด้านหลังของหนูตะเภา โดยแผลทั้งสองข้างเหมือนกันทุกประการ หลังจากนั้นปิดแผลด้านซ้ายด้วยวัสดุปิดแผลที่เตรียมจากโปรตีนไหมในรูปของไฮโดรเจลและแผลด้านขวาปิดด้วยวัสดุปิดแผลคิวติโนวา ไฮโดร ในวันเก็บชิ้นเนื้อ สังเกตแผลและถ่ายภาพขนาดของแผลด้วยกล้องถ่ายภาพดิจิตอล นำภาพที่ได้มาคำนวณหาขนาดของพื้นที่แผลโดยใช้โปรแกรมวิเคราะห์ภาพทางคอมพิวเตอร์ นำเนื้อเยื่อบริเวณบาดแผลนั้นมาศึกษาลักษณะทางจุลกายวิภาคศาสตร์ด้วยกล้องจุลทรรศน์แบบใช้แสงเพื่อศึกษาขบวนการสมานแผล ผลการ ศึกษาพบว่า แผลที่ปิดด้วยวัสดุปิดแผลที่เตรียมจากโปรตีนไหมในรูปของไฮโดรเจลมีการเจริญของผิวหนังชั้นหนังกำพร้าปิดคลุมบริเวณผิวแผลอย่างสมบูรณ์ในวันที่ 12 นับจากวันที่สร้างแผล ส่วนแผลปิดด้วยวัสดุปิดแผลคิวติโนวา ไฮโดร จะปิดสมบูรณ์ในวันที่ 15 นับจากวันที่สร้างแผล แผลที่ปิดด้วยวัสดุปิดแผลที่เตรียมจากโปรตีนไหมในรูปของไฮโดรเจลจะหายเร็วกว่าแผลที่ปิดด้วยวัสดุปิดแผลคิวติโนวา ไฮโดร เป็นเวลา 3 วัน การศึกษาทางจุลกายวิภาคศาสตร์พบว่า ในทุกวันของการศึกษา แผลที่ปิดด้วยวัสดุปิดแผลที่เตรียมจากโปรตีนไหมในรูปของไฮโดรเจล มีการสร้างเนื้อเยื่อใหม่ในผิวหนังชั้นหนังแท้ที่พัฒนามากกว่าแผลที่ปิดด้วยวัสดุปิดแผลคิวติโนวา ไฮโดร รวมทั้งพบการอักเสบน้อยกว่าแผลที่ปิดด้วยวัสดุปิดแผลคิวติโนวา ไฮโดร ดังนั้นวัสดุปิดแผลที่เตรียมจากโปรตีนไหมในรูปของไฮโดรเจลจึงส่งเสริมให้มีการสร้างผิวหนังทั้งชั้นหนังกำพร้าและชั้นหนังแท้ของบริเวณบาดแผลได้เร็วกว่าวัสดุปิดแผล คิวติโนวา ไฮโดร

Abstract

The effects of the hydrogel biomaterial preparation from silk waste proteins on the deep wounds healing were studied and compared with those of Cutinova® hydro. Twelve female Dunkin Harley Guinea pigs were used in the experiment. They were divided into six groups of two each, regarding to the time they were sacrificed. Those were from day 3 to day 18 of 3 days interval.

Each animal was prepared two mirror image deep wounds on the dorsal body wall. The left wound was dressed with silk-based hydrogel while the right with Cutinova® hydro. After sacrifice, the wound areas were observed and photographed by a digital camera and calculated using the image analysis program for evaluation of the remaining wound area. Then the wound tissues were removed for light microscopy to observe the degree of healing process. The gross and histopathological appearance revealed that the silk-based hydrogel biomaterial was found to be more effective in promoting wound healing without offensive reaction.

Introduction

Silk from the cocoon of silkworm, *Bombyx mori*, contains at least two major fibroin proteins, light and heavy chains, 25 and 325 kDa, respectively. In recent years, fibroin from *Bombyx mori* silkworm has been the dominant source for silk-based biomaterial studies. The unique mechanical properties of these fibers due to the biocompatibility, slow degradability provided important clinical repair options for many applications. Each year, Thailand has abundant waste of silk cocoon from silk industries. Division of Bioscience, Office of Atoms for Peace, Ministry of Science and Technology, Thailand has developed hydrogel biomaterial prepared from those silk waste proteins by irradiation. In this study, its efficacy for deep wound healing *in vivo* was evaluated, in comparison with that of a commercial product (Cutinova® hydro), used in wide-spread.

Materials and Methods

Twelve female Dunkin Harley Guinea pigs purchased from the National Animal Center of Thailand were used in the experiment. Two full thickness excision wounds (1x1 cm^2) were operated on right and left side 1 cm apart from dorsal midline between scapular area in each animal under aseptic technique and condition. The right wound was dressed by Cutinova® hydro (commercial product) while the left was a silk-based hydrogel biomaterial dressing. Throughout the experimental period, animals were kept in individual cage under control-conditioned room, temperature at 25-28°C with 12 hours light per day and fed on standard diet and sterile drinking water. Animals were divided into six groups of two each, regarding to the time they were sacrificed. Those were day 3, 6, 9, 12, 15, and 18 of 3 days interval. After sacrifice, the wound areas were observed and evaluated of gross pathology. Then wound debris was cleaned to reveal the remaining wound area. The wound areas were photographed by a digital camera and calculated using the image analysis program for evaluation of the remaining wound area. Then the wounds and tissue surrounding were excised and removed for histopathological process. The tissues were examined under light microscopy to observe the degree of healing process.

Results and Discussions

The results demonstrated that the healing rate of hydrogel biomaterial dressing was faster than commercial product during the whole experiment period. This study included the analyzer of the wounds size and histological finding of the wound tissue. The size of the wound areas diminished progressively. On day 3, all wounds of each treatment became hyperemia. On day 6, 9, 12, 15, and 18 after dermatotomy, the wounds in all groups showed a progressive decrease in wound size. However, the wounds dressed with silk hydrogel showed a greater progressive decrease in size than those with the Cutinova® hydro, the control wounds. Since day 15 onward, the edges of the wounds were smooth and the wounds revealed no inflammation, as well as not appeared red or swelling. The wounds dressed with silk hydrogel were completely covered with skin on day 15 while those with Cutinova® hydro still appeared on day 18, the last experimental day (Figure 1).

Concerning the graph demonstrating the remaining wounds areas, the silk hydrogel-dressed wounds disappeared on day 18 whereas those of Cutinova® hydro almost disappeared and the average percents of the remaining wound was 1.8% (Figure 2).

The histological finding was performed in three aspects including epidermal assessment, granulation tissue determination and evaluation of inflammatory cells. In the wounds dressed with silk hydrogel, the epithelialization was early performed on day 3 after dermatotomy from the edges of the wound surfaces while those with the Cutinova® hydro on day 6. The silk hydrogel-dressed wounds showed more advanced developing epidermis and were completely closed on day 12 while the Cutinova® hydro-dressed wounds were completely closed on the day 15.

All of the experimental wounds dressed with both materials revealed the progressive healing process those were the granulation tissue made an advance from day 3 to day 18 after dermatotomy. However, the wounds dressed with silk hydrogel always displayed more advanced granulation tissue which showed more newly formed blood vessels, fibroblast and neatly arranged collagen fiber than those with Cutinova® hydro. Besides, on day 18, the silk hydrogel-dressed wounds showed the dermal appearance, dense irregularly arranged connective tissue like in the intact normal skin. The healing effect of silk hydrogel was mediated by both re-epithelialization via rapid proliferation of epithelial cell and collagen deposition via fibroblast proliferation.

In addition, the infiltration of inflammatory cells in the wounds dressed with silk hydrogel was less than those in the Cutinova® hydro-dressed wounds. The amount of inflammatory cells found in the wounds dressed with silk hydrogel was classified as moderate to few and progressively decreased on day 3 to day 18. Where as, the Cutinova® hydro-dressed wounds showed the amount classified as many to moderate. Moreover, in the middle part of the Cutinova® hydro-dressed wounds demonstrated more foreign body giant cells and macrophages than those of silk hydrogel-dressed wounds (Figure 3).

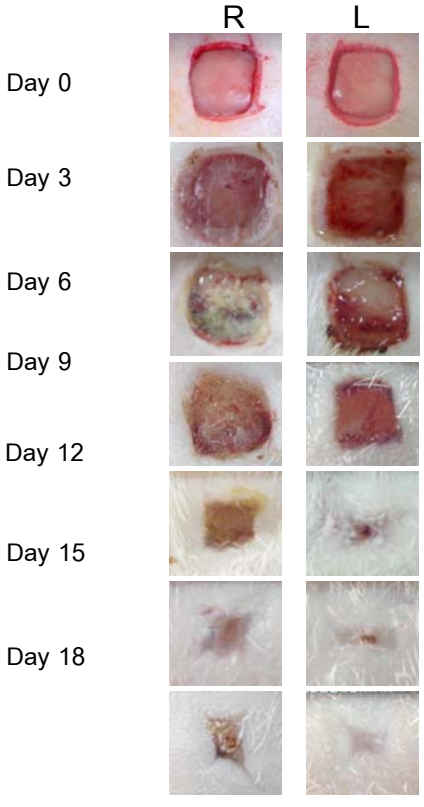

Figure 1 Photographs of the wound surfaces show the progress of the wound healing process. The wounds dressed with Cutinova® hydro are shown in the R column and those dressed with silk hydrogel in the L column

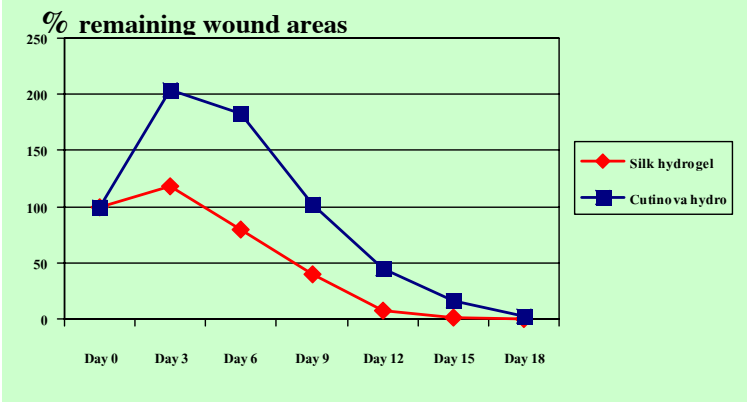

Figure 2 The average percentages of the remaining wound areas as a function of a treating day. Comparison between wounds dressed with silk hydrogel and Cutinova® hydro.

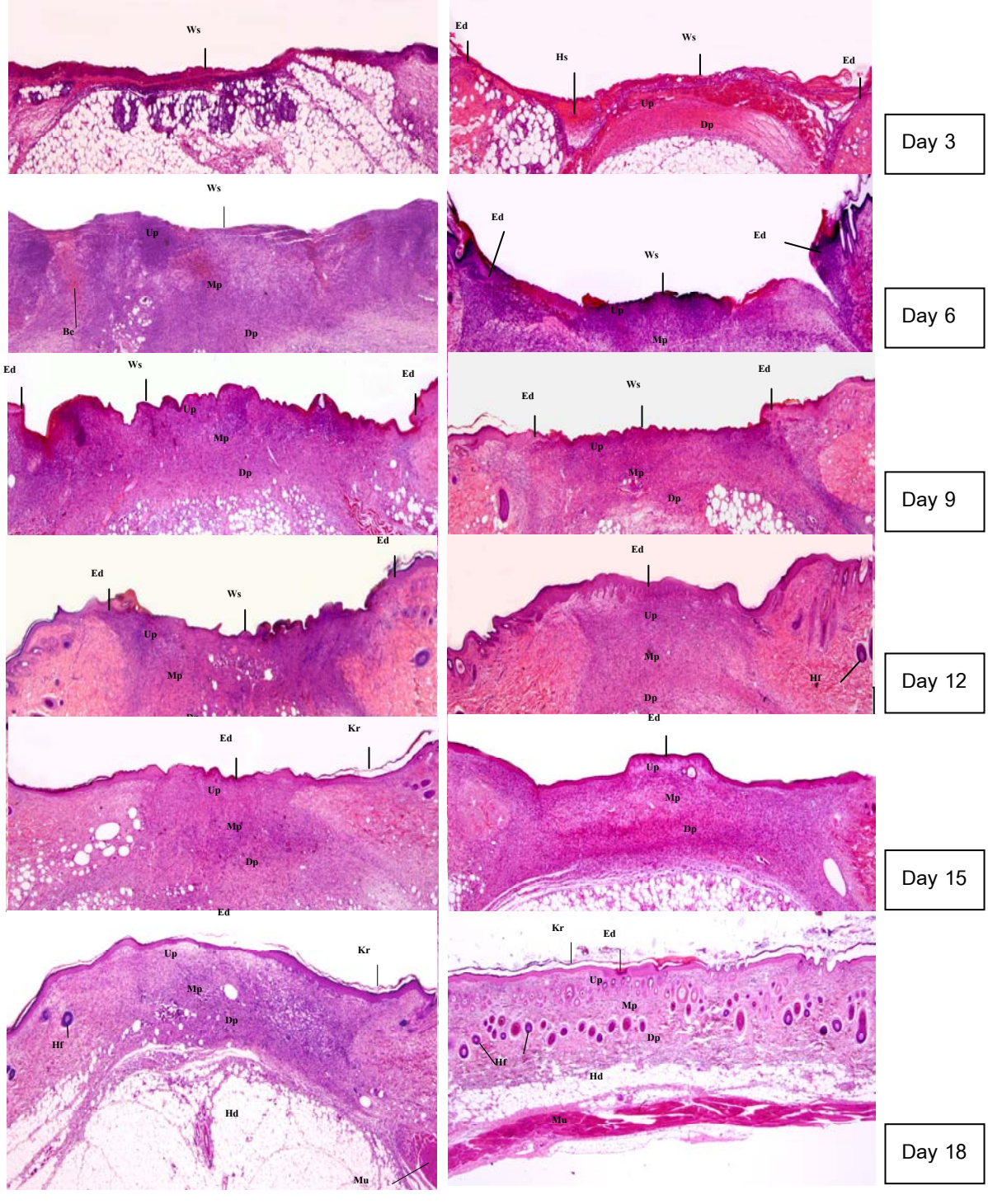

Figure 3 Histopathological finding of wound tissue dressed with Cutinova® hydro (Right column) and silk hydrogel (Left column). They were analyzed in three aspects including epidermal assessment, granulation tissue determination and evaluation of inflammatory cell. (Ws: wound surface, Ed: epidermis, Hs: homogenous substances, Kr: keratin, Hf: hair follicle, Up: upper part of the wound, Mp: middle part of the wound, Dp: deep part of the wound)

Conclusions

All of the experimental wounds dressed with both materials revealed the progressive healing process. However, silk hydrogel biomaterial dressing demonstrated more effectively in promoting wound healing than the commercial product. On comparison of this findings indicated that silk hydrogel biomaterial preparation was beneficial and alternative in clinical use for skin wound application.

Acknowledgement

This research was financially supported by Office of Atoms for Peace, Ministry of Science and Technology, Bangkok, Thailand.

References

1. Rujiravanit R, Kruaykitanon S, Jamieson AM, Tokura MS. Preparation of crosslinked chitosan/silk fibroin films for drug delivery system. Biosci 2003; 3: 604.
2. Santin M, Motta A, Freddi G, Cannas M. In vitro evaluation of the inflammatory potential of the silk fibroin. J Biomed Mater Res 1999; 46: 382-389.
3. Ayub ZH, Arai M, Hirabayashi K. Quantitative structural analysis and physical properties of silk fibroin hudrogels. Polymer 1994; 35: 2197-2204.